

Complex Aortoiliac Aneurysm Management

A case in which synchronous fenestrated stent grafting and iliac branch devices are used for exclusion of an aortoiliac aneurysm.

BY BIBOMBE P. MWIPATAYI, MMED (SURG), FCS (SA), FRACS;
SHANNON THOMAS, BMEDSC HONS, MBBS (HONS); AND KYLIE LUCA, MBBS

Since its first description by Parodi and colleagues, endovascular aneurysm repair has evolved with the development of advanced devices allowing the treatment of difficult anatomy.^{1,2} In particular, challenges faced by present-day devices include short proximal aneurysm necks, suprarenal and infrarenal angulation, and concomitant common iliac and internal iliac artery aneurysms.

The use of fenestrated grafts was first reported by Lawrence-Brown and colleagues, whereby short aneurysm necks could be treated by extending the sealing zone to the juxtarenal aorta, creating windows through which flow to the renal arteries, superior mesenteric, and even celiac arteries could be maintained.^{3,4}

The Zenith Iliac Branch Devices (IBDs) (Cook Medical, Brisbane, Australia) allow an endoluminal graft to seal in the external iliac artery while maintaining internal iliac artery flow through a branch. These devices were first developed for patients with aortoiliac or iliac aneurysms and insufficient sealing sites within the common iliac artery. The unique side branch allows blood flow to the

“... endovascular aneurysm repair has evolved with the development of advanced devices allowing the treatment of difficult anatomy.”

internal iliac artery, reducing the potential for ischemic sequelae (not available for sale in the United States).⁵

This article discusses a case of a 74-year-old woman with complex aortoiliac aneurysms that required simultaneous renal fenestration and an iliac bifurcation device for successful exclusion of her aneurysm.

TECHNIQUE

The patient presented with an incidental finding on computed tomographic (CT) scan of an aortoiliac aneurysm. She had a medical history of hypertension, hypothyroidism, and total radical abdominal hysterectomy.

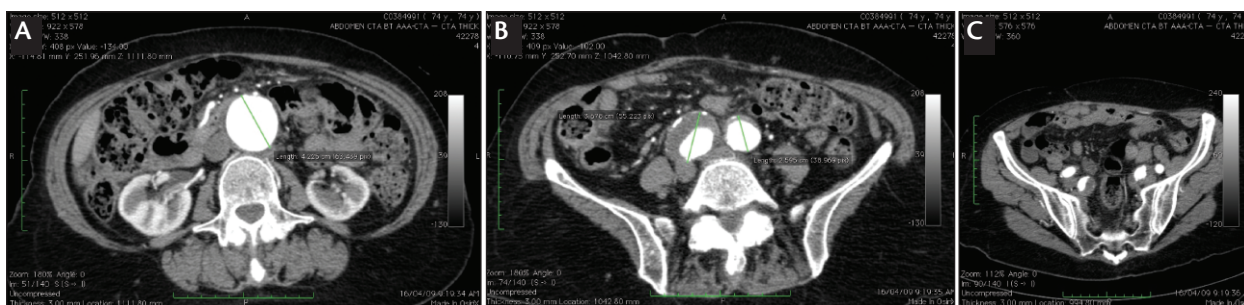


Figure 1. An aortic aneurysm scan demonstrated an infrarenal abdominal aortic aneurysm with a maximum anteroposterior diameter of 4.2 cm (A). An iliac artery aneurysm CT scan revealed that both common iliac arteries' origins were aneurysmal, with the right measuring 3.6 cm in maximum diameter and the left measuring 2.5 cm. (B). The internal iliac arteries were also aneurysmal, with the right measuring 2.1 cm in diameter. The external iliac arteries were normal, with minimal atherosclerotic disease (C).

CHALLENGING CASES

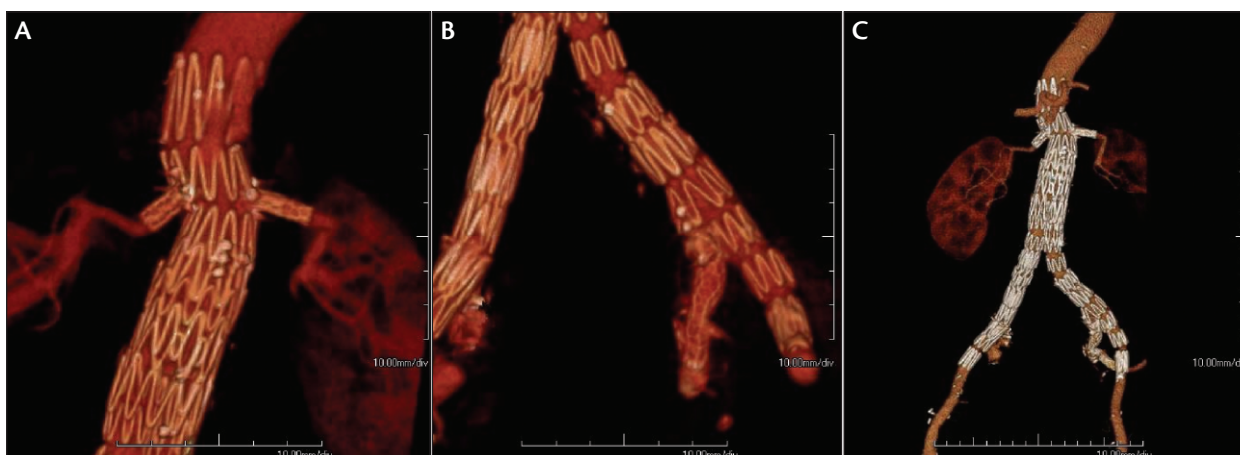

Figure 2. A three-dimensional volume-rendering CT reconstruction of the proximal part of the fenestration graft showing a patent Advanta V12 stent (Atrium Medical Corporation, Hudson, NH) in both renal arteries. The stents are well-flared and positioned adequately (A). A three-dimensional volume-rendering CT reconstruction of the IBD stent showing a patent Advanta V12 stent in the left internal iliac artery (B). A three-dimensional multiplanar CT reconstruction of the fenestration stent graft and IBD (C).

The complexity of her aneurysm anatomy is shown in Figure 1. The CT scan showed an infrarenal abdominal aortic aneurysm with a maximum anteroposterior diameter of 4.2 cm (Figure 1A). The origins of both common iliac arteries were aneurysmal, with the right measuring 3.6 cm in maximum diameter and the left measuring 2.5 cm (Figure 1B). The internal iliac arteries were also aneurysmal, with the right measuring 2.1 cm in diameter (Figure 1C). The renal artery origins were normal, as were the origins of both the superior mesenteric artery and celiac axis.

The right internal iliac artery was initially successfully occluded with an Amplatzer plug (AGA Medical Corporation, Plymouth, MN) and Interlocking detachable coils (IDC) (Boston Scientific Corporation, Natick, MA) before any definitive treatment of the aortoiliac aneurysm.

Because of the complexity and length of the procedure, general anesthesia was preferred, and access to the common femoral artery was obtained by surgical cutdown. The aneurysm treatment procedure began with bilateral common femoral artery exposures with 5-F arterial punctures. After establishing Lunderquist extra stiff wires (Cook Medical, Bloomington, IN) in the aorta, the fenestrated device was introduced first into the juxtarenal aorta with preloaded wires in the device for renal cannulation. A 5-F Sos Omni catheter (AngioDynamics, Queensbury, NY) and a 0.035-inch, 180-cm Glidewire (Terumo Interventional Systems, Somerset, NJ) were placed through the device to cannulate each renal artery, after which the device was

deployed fully. Advanta V12 stents (7 X 38 mm) were then deployed within the renal arteries, with flaring of the stents within the fenestration holes of the main device to allow for sealing (Figure 2A).

The IBD was then introduced through the left groin, and after the branched wire was snared in the aorta, a 10- and 7-F flexor sheath was telescoped into the device. After careful positioning, the device was deployed, and an Advanta V12 stent (9 X 59 mm) was deployed into the internal iliac via the contralateral approach. The IBD used in this series was derived from the Cook Zenith TFLE leg extension (Cook Medical). A side branch was attached to the leg in a 30° angle. The proximal diameter of the device was 12 mm, and the diameter of the side branch was 8 mm. For the distal diameter of the device, one can opt for 10 or 12 mm. An indwelling catheter was passed through the internal iliac branch. All aortic stent graft components used in conjunction with the IBD were Zenith Flex graft components (Cook Medical) (Figure 2B).

A bridged device was deployed inferior to the fenestrated graft where the contralateral gate was cannulated to join the branched device to the bridging graft. The right iliac limb grafts were deployed to seal the aneurysm in the external iliac artery. Final digital subtraction angiography did not reveal any endoleak. After closure of the groin wounds, the patient was admitted to a monitored unit for close observation (Figure 2C). The procedure time was 3 hours and 30 minutes. The patient made an unremarkable recovery and was discharged 5 days later.

CHALLENGING CASES

“Stent grafts with an internal iliac artery side branch offer an opportunity to repair aortoiliac aneurysms without sacrificing the internal iliac artery.”

DISCUSSION

This is the first time a synchronous Zenith fenestrated stent graft and a Zenith iliac branch graft have been used in the same procedure.⁶ A custom Zenith fenestrated stent graft allows placement of an endoluminal stent graft above the renal arteries without interrupting renal blood flow. Each fenestration is equipped with radiopaque markers that allow precise placement of each fenestration. These allow treatment options for patients with proximal infrarenal necks ranging from 4 to 15 mm in length and 19 to 31 mm in diameter.⁷

The Zenith IBD allows for the management of patients with aortoiliac or iliac aneurysms with insufficient sealing sites within the common iliac artery. The preloaded catheter facilitates internal iliac cannulation. The independent Z-stent design provides graft flexibility and columnar strength. Stent grafts with an internal iliac artery side branch offer an opportunity to repair aortoiliac aneurysms without sacrificing the internal iliac artery. Implantation of the internal iliac artery branch graft is more complex than routine endovascular aneurysm repair.^{5,8,9}

Both of these complex devices require the use of bridging stent grafts. Three types are available in the market: Advanta V12 polytetrafluoroethylene stent, the Jostent stent graft peripheral (Abbott Vascular, Santa Clara, CA), and the Fluency stent graft (Bard Peripheral Vascular, Inc., Tempe, AZ).

The Advanta V12 polytetrafluoroethylene stent was used to ensure sealing of the fenestration to the visceral vessels and then to the internal iliac artery. Technical success was defined as exclusion of the aneurysm with preservation of flow to the internal iliac artery.

There are specific steps in this challenging procedure that should be followed, beginning with the careful planning of the case and possible pullout if required. Additionally, the fenestrated stent graft should be inserted first, and there should be correct sizing of the V12 stent to avoid unnecessary manipulation of the device with potential distal embolization. This should be followed by insertion of the IBD with deployment of the V12 stent. Finally, the bifurcated stent graft should

be deployed, followed by deployment of the bridging stent. Unnecessary movement of the deployed device can occur, and care must be taken to avoid this.

CONCLUSION

We have demonstrated the challenges of performing synchronous fenestrated stent grafting with the deployment of an IBD. Although the procedure involves multiple intricate steps and is therefore time consuming, if well planned and carefully performed, the outcome is satisfactory and durable. We agree with the development of endovascular solutions to treat more difficult aneurysm anatomy with a durable result. ■

Bibombe P. Mwipatayi, MMed (Surg), FCS (SA), FRACS, is an endovascular surgeon with the Department of Vascular Surgery at Royal Perth Hospital, Professor of Surgery at the School of Surgery, and Faculty of Medicine, Dentistry, and Health Sciences at the University of Western Australia in Perth, Australia. He has disclosed that he receives grant/research funding from Atrium Medical. Dr. Mwipatayi may be reached at +61-8-9224 0228; bibombe@inet.net.au.

Shannon Thomas, BMedSc Hons, MBBS (Hons), is a vascular fellow with the Department of Vascular Surgery at Royal Perth Hospital in Perth, Australia. She has disclosed that she holds no financial interest in any product or manufacturer mentioned herein. Dr. Thomas may be reached at +61-8-9224 2191; shannondthomas@gmail.com.

Kylie Luca, MBBS, is a surgical resident with the Department of Vascular Surgery at Royal Perth Hospital in Perth, Australia. She has disclosed that she holds no financial interest in any product or manufacturer mentioned herein. Dr. Luca may be reached at +61-8-9224 2191; kluca85@gmail.com.

1. Parodi JC, Palmaz JC, Barone HD. Transfemoral intraluminal graft implantation for abdominal aortic aneurysms. *Ann Vasc Surg.* 1991;5:491-499.
2. Greenberg RK, Lawrence-Brown M, Bhandari G, et al. An update of the Zenith endovascular graft for abdominal aortic aneurysms: initial implantation and mid-term follow-up data. *J Vasc Surg.* 2001;33(2 suppl):S157-164.
3. Semmens JB, Lawrence-Brown MM, Hartley DE, et al. Outcomes of fenestrated endografts in the treatment of abdominal aortic aneurysm in Western Australia (1997-2004). *J Endovasc Ther.* 2006;13:320-329.
4. Anderson JL, Berce M, Hartley DE. Endoluminal aortic grafting with renal and superior mesenteric artery incorporation by graft fenestration. *J Endovasc Ther.* 2001;8:3-15.
5. Malina M, Dirven M, Sonesson B, et al. Feasibility of a branched stent-graft in common iliac artery aneurysms. *J Endovasc Ther.* 2006;13:496-500.
6. Resch TA, Greenberg RK, Lyden SP, et al. Combined staged procedures for the treatment of thoracoabdominal aneurysms. *J Endovasc Ther.* 2006;13:481-489.
7. Greenberg RK, West K, Pfaff K, et al. Beyond the aortic bifurcation: branched endovascular grafts for thoracoabdominal and aortoiliac aneurysms. *J Vasc Surg.* 2006;43:879-886; discussion 886-887.
8. Haulon S, Greenberg RK, Pfaff K, et al. Branched grafting for aortoiliac aneurysms. *Eur J Vasc Endovasc Surg.* 2007;33:567-574.
9. Tielliu IF, Bos WT, Zeebregts CJ, et al. The role of branched endografts in preserving internal iliac arteries. *J Cardiovasc Surg (Torino).* 2009;50:213-218.